

Let's Talk TB

A Series on Tuberculosis, A Disease That Affects Over 2 Million Indians Every Year

BARRY RABINOVITCH, MD, FRCP(C)—Author

MADHUKAR PAI, MD, PHD—Co-author and Series Editor

Barry Rabinovitch is an assistant professor of medicine at McGill University, Montreal and a respirologist at the Montreal Chest Institute, McGill University Health Centre, Montreal.

Madhukar Pai is a TB researcher and an associate professor of epidemiology and Biostatistics at McGill University in Montreal, Canada. He has served as co-chair of the Stop TB Partnership's Working Group on New Diagnostics. He holds honorary professorship positions at the Christian Medical College, Vellore, India; University of Cape Town, South Africa; and Stellenbosch University, South Africa.

Interpretation of Chest X-rays in Tuberculosis

Abstract

Every GP in India will need to consider TB as a differential diagnosis in persons with cough lasting two weeks or more, or with unexplained chronic fever and/or weight loss. Chest radiography is very widely used in India. Chest x-rays serve as an invaluable adjunct in the diagnosis and follow-up of TB. However, TB may mimic other diseases on x-rays, and non TB conditions may look like TB. Thus, chest x-rays are neither specific nor sensitive, and so remain a supplement to microbiological tests such as microscopy, PCR and culture. Treatment of TB purely on the basis of x-rays can result in significant over-treatment with adverse consequences for patients. Therefore, all persons with chest radiographic findings suggestive of TB should have sputum specimens submitted for microbiological examination. This article provides a series of x-rays that serve to educate the provider about radiological interpretation of TB and common pitfalls and errors in interpretation.

Key words: tuberculosis, diagnosis, radiology, chest x-rays

INTRODUCTION

The definitive diagnosis of active pulmonary TB is made by sputum microscopy, rapid molecular tests (e.g., PCR) and culture.^{1,2} Chest x-rays serve as an invaluable adjunct in the diagnosis and follow-up of this disease. In the event of negative cultures, it can provide the only way to suspect active disease and is useful in the assessment of treatment response. However, TB may mimic other diseases on x-rays, and non TB conditions may look like TB. Thus chest x-rays are neither specific nor sensitive, and so remain a supplement to microscopy, PCR and culture.^{1,2}

The radiologic appearance of TB reflects the host response to infection. TB infects the lung by inhalation of droplets from a person with active disease. In 90% of patients, the infection remains latent. In approximately 5% it progresses to active disease within a short period, causing primary disease. In the remaining 5%, it may remain latent for many years before reactivating, causing reactivation, or post primary disease. The radiologic appearance of primary versus reactivation TB is very different. Most of the cases you will see in your practice are reactivation disease. Most children develop primary disease and their radiological presentation can be different from adults (radiology in children is not covered in this article).

TB can involve the pulmonary parenchyma, interstitium, pleura, pericardium and bone, each resulting in a different radiologic picture. In general, the presence of upper-lobe opacities, cavities, a unilateral pleural effusion, and hilar or mediastinal lymphadenopathy may be the most useful radiological markers of pulmonary TB.^{3,4}

The following chest x-rays (CXR's) illustrate the different radiologic manifestations of TB. There are also cases that are not TB, but look like TB. Finally, there are cases that look like other diseases but eventually turned out to be TB. HIV infection is the most common reason for atypical radiographic appearance in TB patients. The altered ra-

Let's Talk TB

Interpretation of Chest X-rays
in Tuberculosis

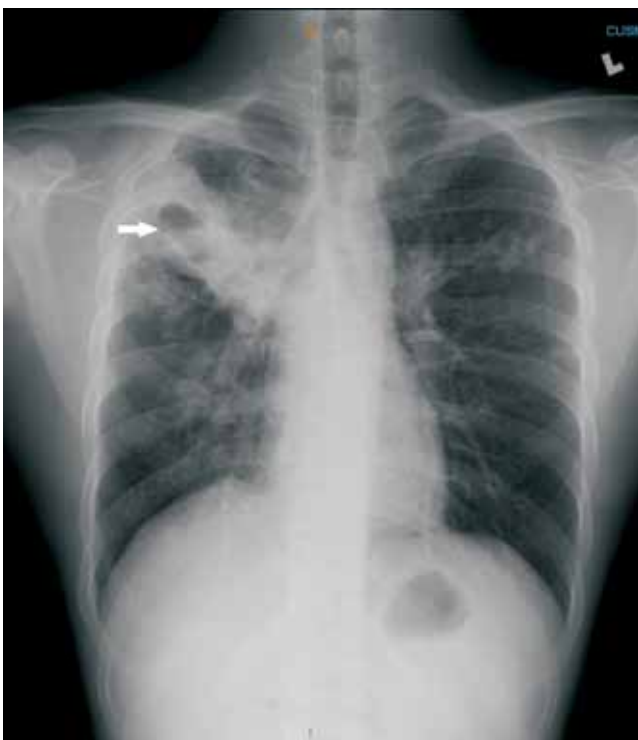

Figure 1 – Classical picture of active pulmonary TB

diographic appearance of pulmonary TB in patients with HIV is due to compromised immunity.

Quality of radiographs is important to consider, and films should be read carefully as inter- and intra-reader

variations are common.⁵ All x-rays must be interpreted with relevant clinical and laboratory data.

CLASSICAL TB

In **Figure 1** you can see the classical picture of active pulmonary TB. There is bilateral airspace disease, much more prominent in the right lung. There are also multiple cavities in the RUL (right upper lobe). Although this is typical of TB, if the history was an acute one, i.e., a 5 day history of cough and high fever, the diagnosis would more likely be an aerobic bacterial infection, i.e., staphylococcus or a gram negative pneumonia. CXR's must always be interpreted in light of the clinical history!

THE LORDOTIC CXR

The lordotic CXR is useful in visualizing the apical structures of the lung. Because of the overlap of clavicle, the first rib and posterior ribs, lesions at the apex can be missed. In the lordotic view, the x-ray beam is angled up through the chest, as shown in **Figure 2**, shifting anterior structures (clavicle and first rib, superiorly), affording a better view of the apices

In **Figure 3a**, the patient was suspected of having a lesion behind the left 2nd rib (arrow). A lordotic CXR (**Figure 3b**) confirmed this to be a cavitory lesion, and sputum sample grew TB on culture.

MINIMAL TB

Early stages of TB can cause minimal radiologic

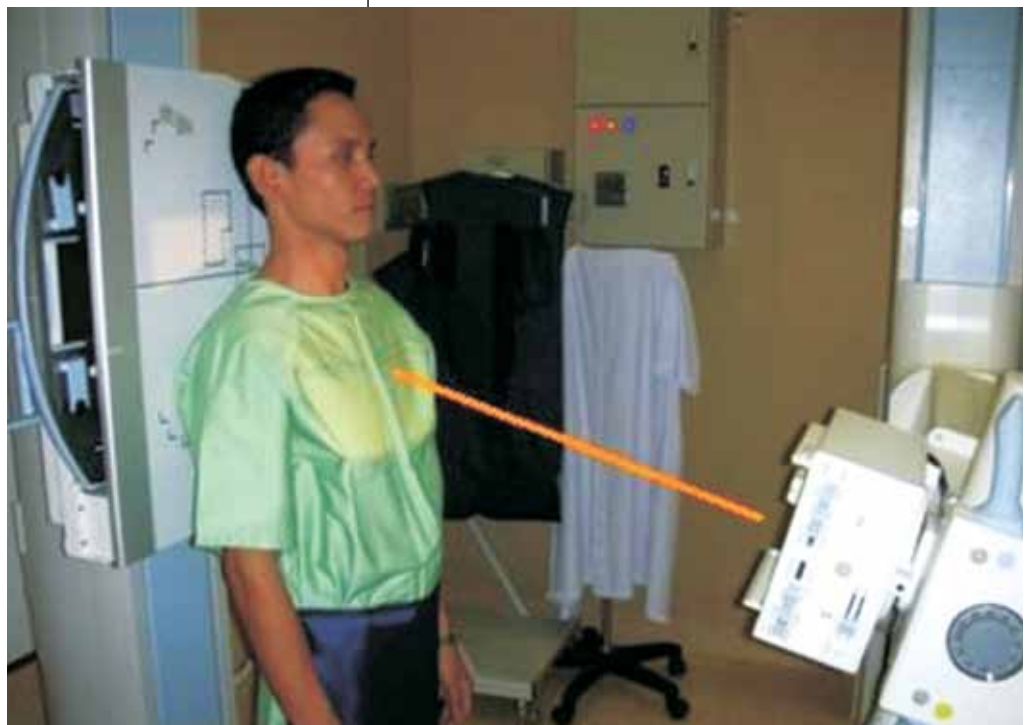


Figure 2 – Principle behind the lordotic CXR (Source: <http://nexradiology.blogspot.ca>)

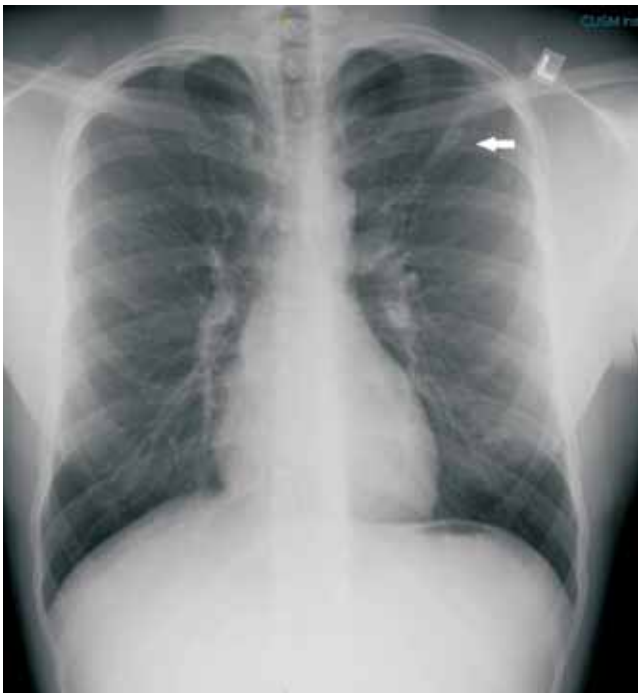


Figure 3a – In this patient, a lesion was suspected (arrow), but hidden by the left 2nd rib

changes. In **Figure 4**, a routine screening film showed minor densities in the LUL (left upper lobe). Sputum induction was done and the sample grew active TB. Sputum cultures are important whenever there is parenchymal disease. If the patient is not coughing, spontaneous sputum is of little value. Sputum induction is very helpful in getting a sample.

LOCATION OF DISEASE

TB prefers the apices of the lung, but that also applies to the lower lobes apices, i.e., the superior segments. **Figure 5** illustrates a case of cavitory TB affecting the superior segment of the RLL (right upper lobe).

EXTENSIVE DISEASE

Figure 6 shows that TB can be very extensive and, in this case, destroying the entire left lung, and also involving the right apex. Note also the lack of soft tissues under the skin of the chest wall, indicating extreme cachexia. The patient subsequently died of his disease. Extensive, cavitory TB is, sadly, common in India and late diagnosis and treatment is a major reason for this.

CULTURE-NEGATIVE TB

In cases where the CXR and clinical history is very suggestive of TB but smears are negative, treatment can be started pending culture results. Negative cultures but

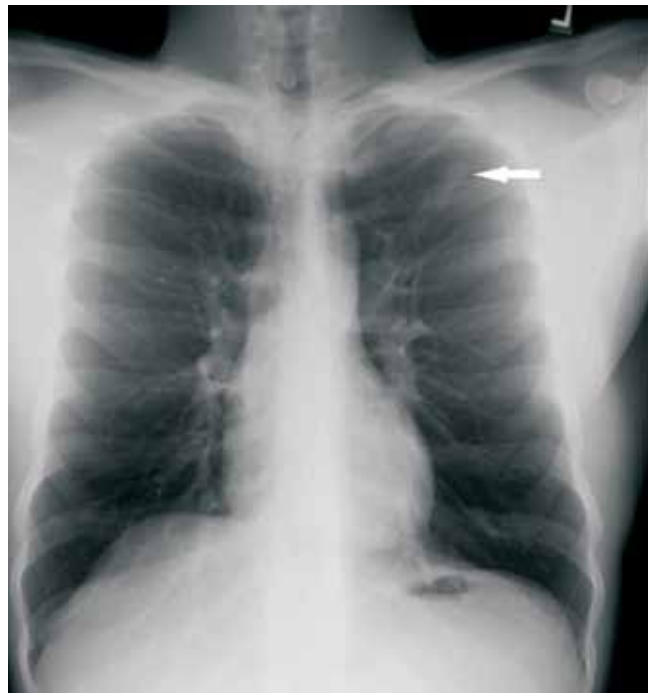


Figure 3b – Lordotic film on the patient in Figure 3a showed cavitory lesion (arrow) and culture grew TB

x-ray improvement on therapy is suggestive of culture-negative TB. Remember that even in the context of good sputum collection with induction, three sputum cultures have a sensitivity of 90%, which means you will miss 10% of cases of active TB. In the following case (**Figure 7a**) the patient was from a TB endemic country, had a positive Mantoux skin test and a one month history of cough.

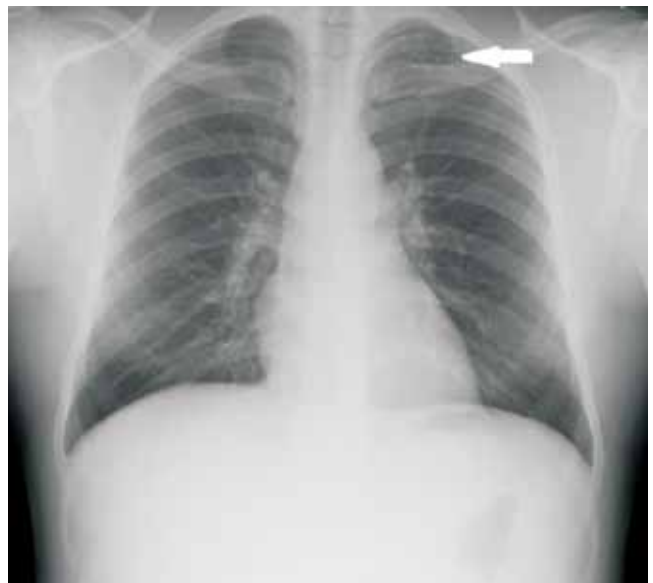

Figure 4 – Minimal TB with minor densities in the LUL. Induced sputum grew TB on culture

Let's Talk TB

Interpretation of Chest X-rays
in Tuberculosis

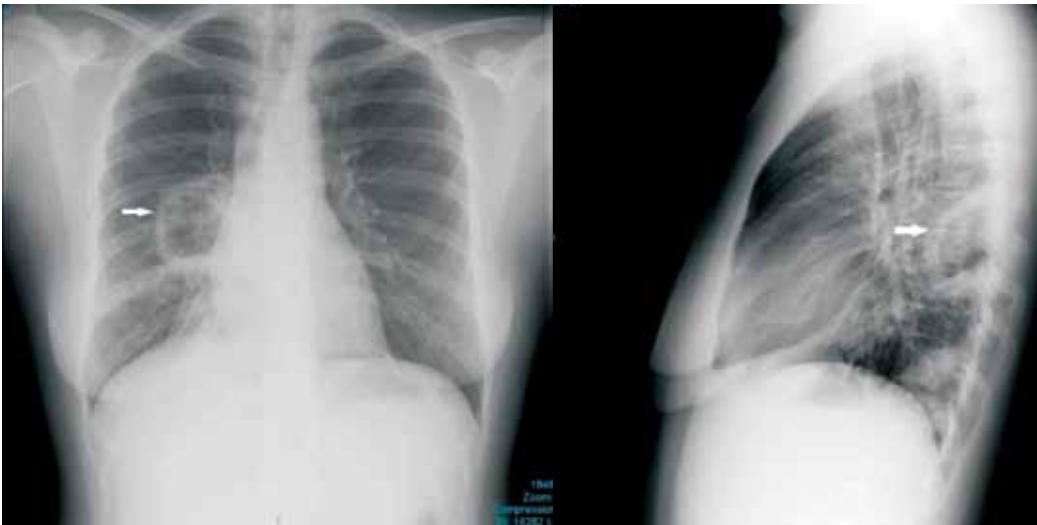


Figure 5 – Cavitary TB affecting the superior segment of the RLL (arrow points to a thick walled cavity)

Three sputum smears and cultures were done and the patient was started on TB drugs. All cultures were negative but a CXR one month later showed resolution of the infiltrates (**Figure 7b**)

PLEURAL TB

Pleural effusion is a common manifestation of TB. It can be a consequence of both primary and reinfection TB. It often resolves with proper antibiotic therapy, but can leave residual pleural thickening and even calcification. **Figure 8a** is a case of a young patient from a TB endemic country who presented with a one month

history of fever and left sided chest pain. Thoracentesis revealed an exudate with low glucose, low pH and a high lymphocyte count. A presumptive diagnosis of TB was made and TB medications were started. The fluid was smear negative (as is often the case in pleural TB) but the cultures grew MTB. The subsequent CXR taken six months later (**Figure 8b**) shows reabsorption of the fluid with residual pleural thickening.

In another case (**Figure 8c**), extensive pleural calcification has developed. This often occurred in the pre-antibiotic era, when recurrent pneumothoraces were induced in the hope of reducing the size of the

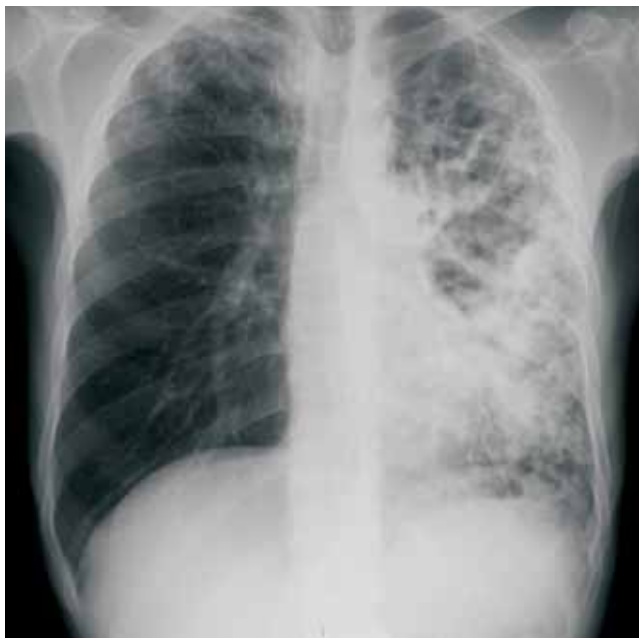

Figure 6 – Extensive, cavitary TB, with destruction of the entire left lung

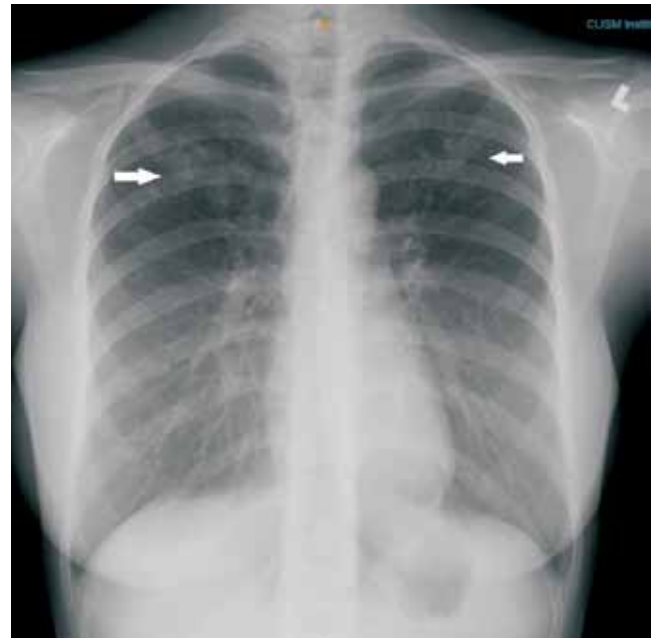


Figure 7a – Arrows point to faint airspace disease in both upper lobes

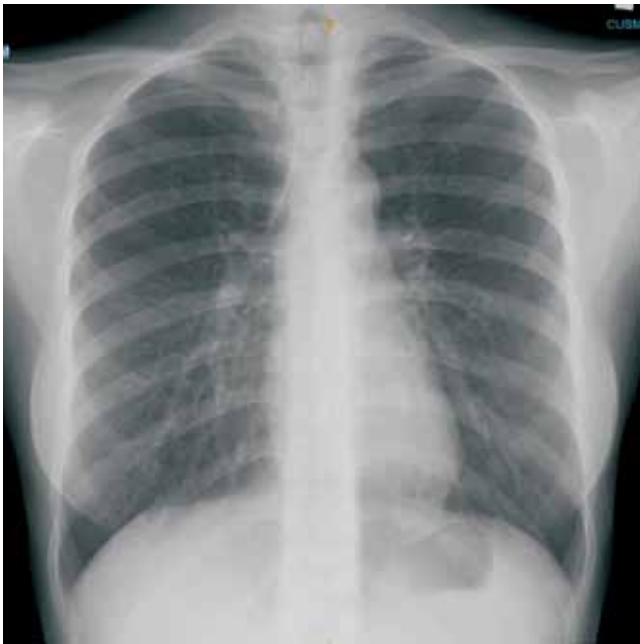

Figure 7b – A CXR shows resolution of the infiltrates after TB therapy

cavity. These pneumothoraces often resulted in repeated infections of the pleural space and subsequent calcification.

MILIARY TB

Miliary TB is a result of hematogenous dissemination of the mycobacteria. It presents with a micronodular

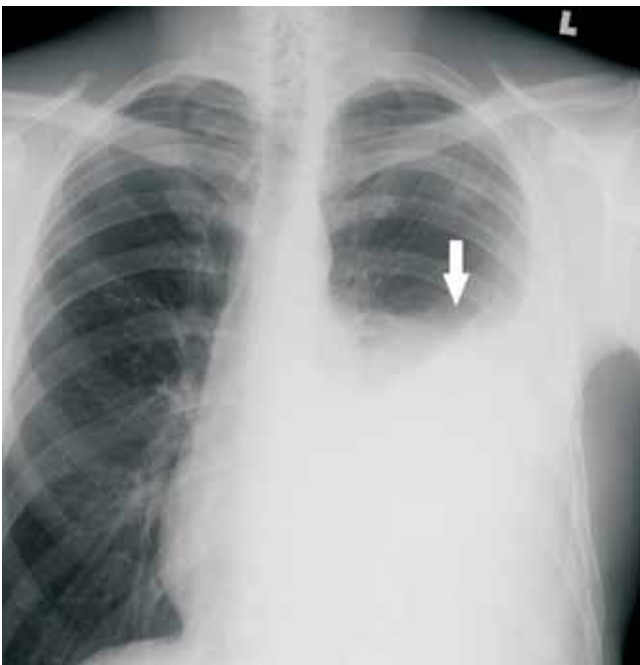


Figure 8a – This CXR shows a large left pleural effusion

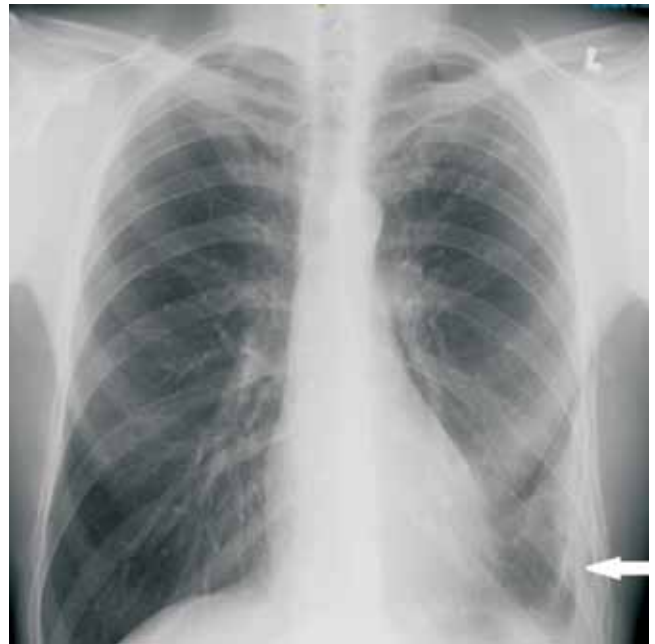

Figure 8b – On this CXR, the arrow points to pleural thickening (earlier CXR shown in Figure 8a)

(1-4 mm in size) pattern distributed diffusely though out both lungs (**Figure 9**). It can arise as a result of progressive primary infection or via reactivation.

PRIMARY TB

Primary TB results from the failure of the host to suppress the initial infection. It present as pneumonia in

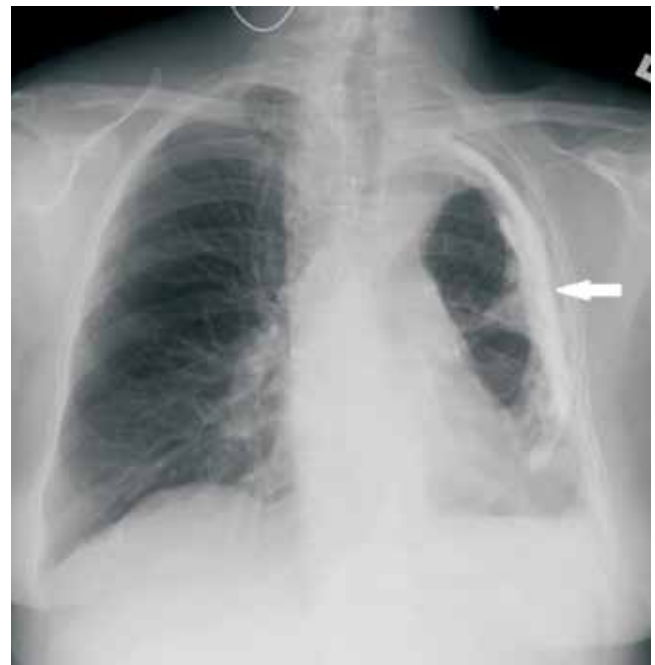


Figure 8c – This CXR shows extensive left pleural calcification

Let's Talk TB

Interpretation of Chest X-rays
in Tuberculosis

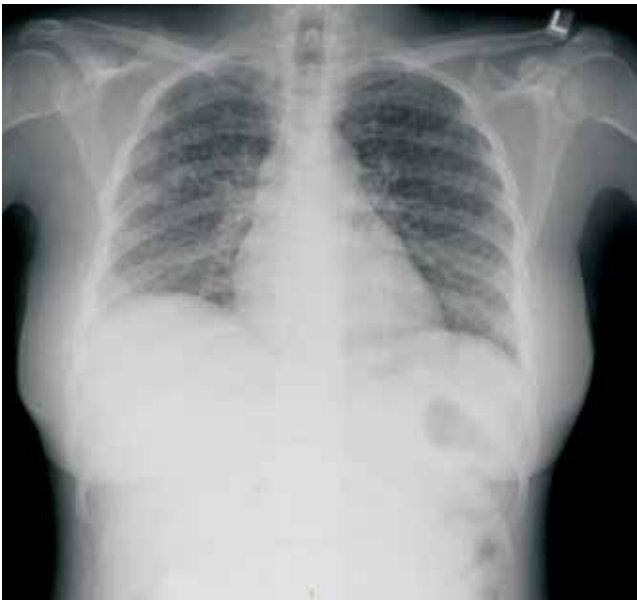

Figure 9 – Miliary TB, with diffuse micronodules distributed throughout both lungs

the lower lobes, lingula or right middle lobe (RML) as opposed to reactivation TB, which tends to favor the apical regions. It can also cause pleural effusion or miliary TB. **Figure 10** shows the CXR of a TB contact who had a 2 week history of cough and fever. Sputum smears and culture were positive.

Another case finding in a TB contact investigation showed a RLL cavity that was smear positive (**Figure 11**).

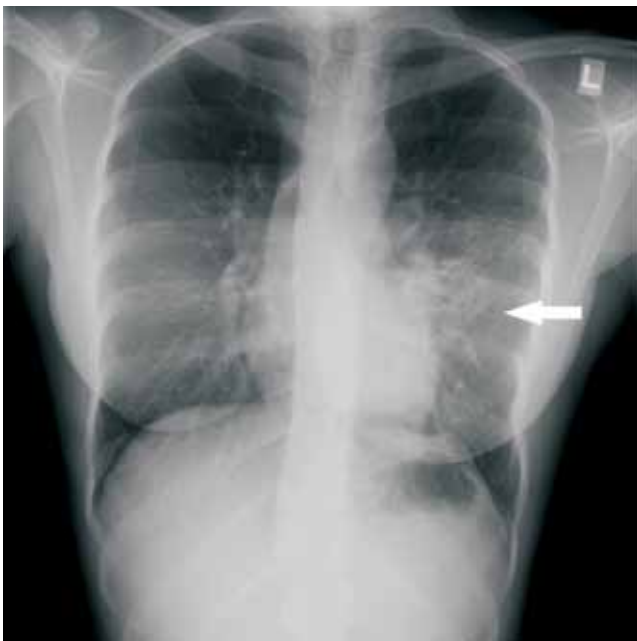


Figure 10 – Infiltrate in lingula in a case of primary TB

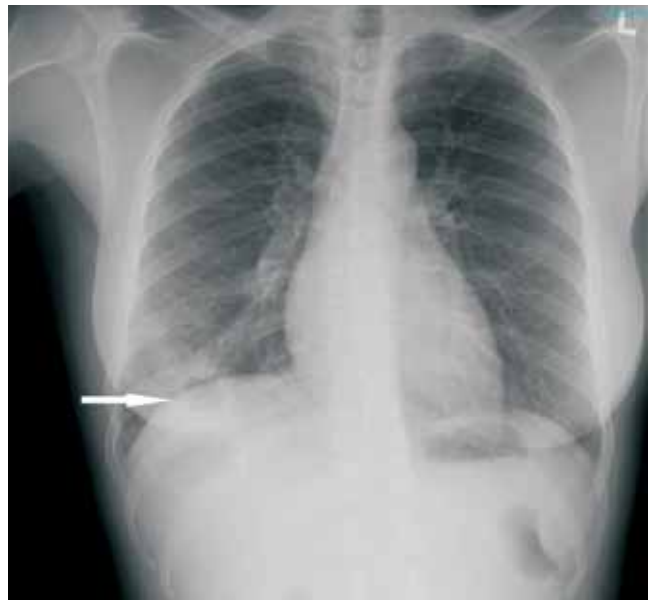


Figure 11 – Arrow points to cavity in the RLL

TB ADENOPATHY

TB adenopathy is a common presentation of extrapulmonary TB. It is often a manifestation of primary TB. It can affect both mediastinal and hilar lymph nodes (**Figure 12**).

TB MAY MIMIC OTHER DISEASES

The CXR below in **Figure 13** is of a 55 year old woman, 30 pack-year smoker, who presented with a one

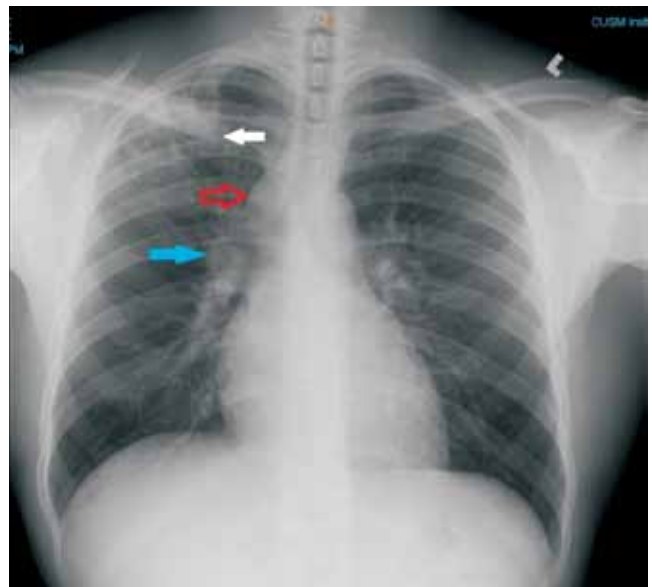


Figure 12 – The white arrow points to an infiltrate in the RUL. The red arrow shows paratracheal adenopathy. The blue arrow points to a right hilar node

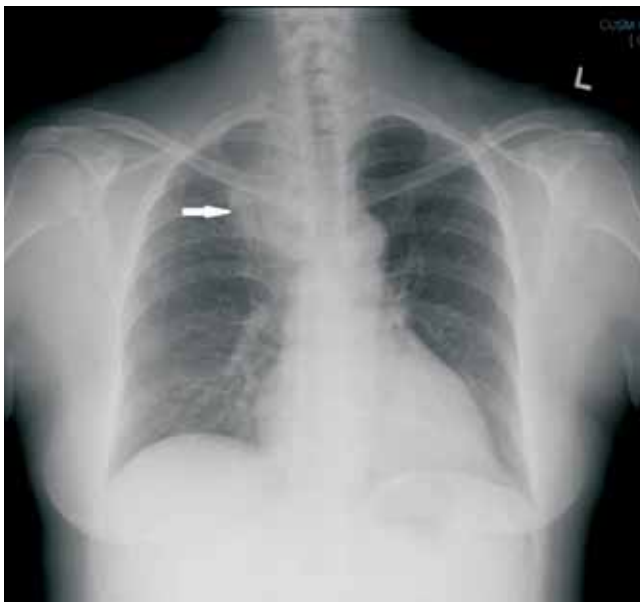

Figure 13 – Mass abutting the mediastinum in the RUL. While cancer was suspected, cultures grew MTB

month history of cough and weight loss. There was no fever. The CXR shows a mass abutting the mediastinum in the RUL. Cancer was suspected and a bronchoscopy was done. Pathology revealed necrotizing granulomas and cultures were positive for TB.

The next case is a 65 year old man, 40 pack-year smoker who had a routine CXR which showed a cavitary nodule in the RUL (**Figure 14**). He was asymptomatic. A CXR done a year previously was normal. Biopsies were

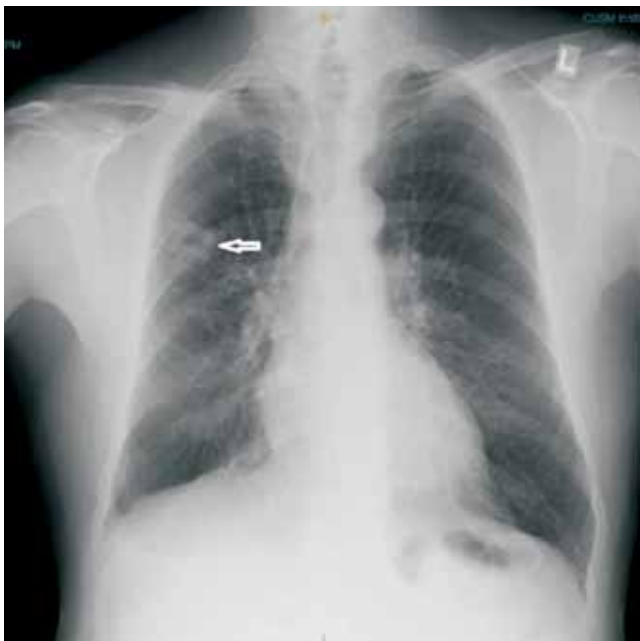


Figure 14 – Arrow points to a cavitary nodule in the RUL

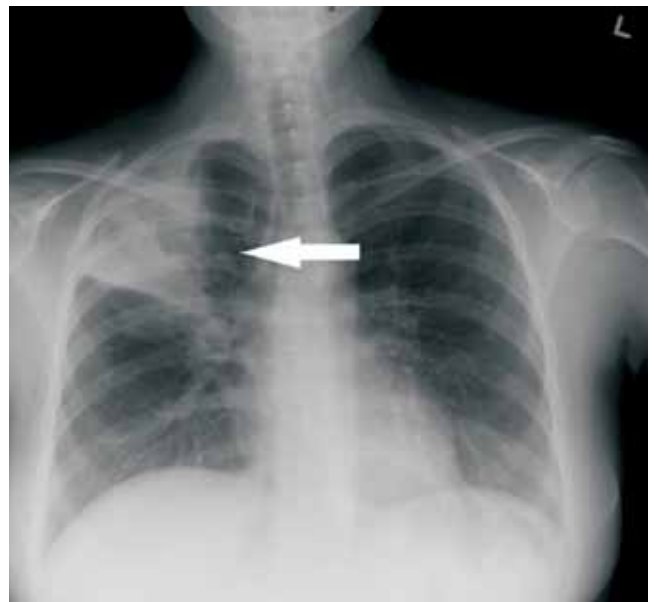


Figure 15a – CXR shows a consolidation in the RUL

negative. Lung cancer was suspected and a thoracotomy was done. The resected lobe showed TB.

DISEASES WHICH MAY MIMIC TB

Figure 15a is CXR of a 40 year old woman who comes from a TB endemic country. The CXR shows a consolidation in the RUL. There was a one week history of fever, chills and cough with purulent sputum. Due to the short history, an acute bacterial pneumonia was

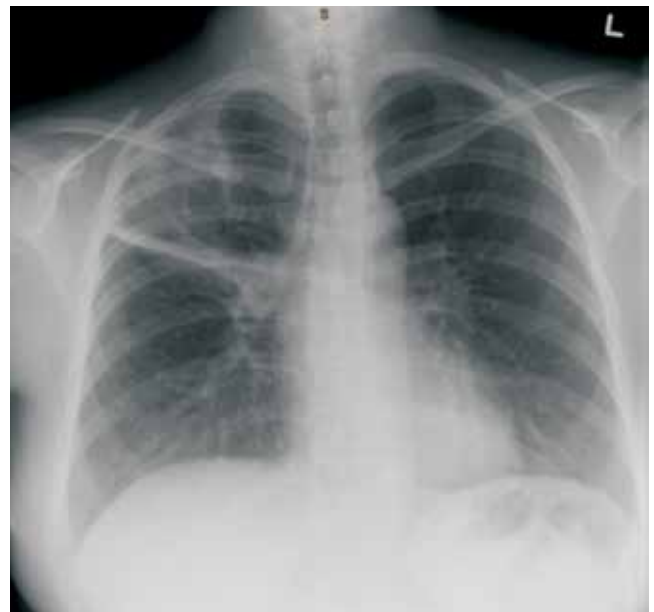


Figure 15b – shows improvement after antibiotic treatment with azithromycin

Let's Talk TB

Interpretation of Chest X-rays
in Tuberculosis

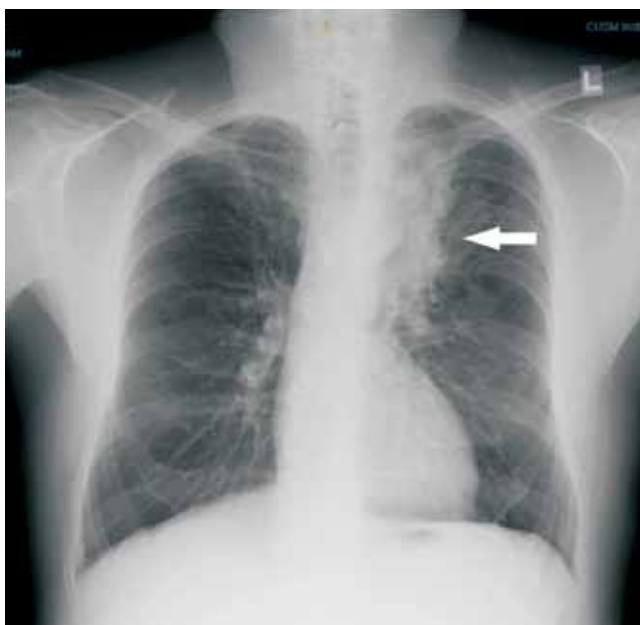


Figure 16a – CXR shows a dense infiltrate in the LUL.

suspected and treatment with azithromycin was started. She promptly became afebrile and the CXR improved within a week. (Figure 15b).

Upper lobe pneumonias in patients from endemic countries should not be treated with fluoroquinolones because if it is TB, it will respond (temporarily) to this class of antibiotics, and make it much harder to diagnose TB later.²

The next case is a 56 year old man with extensive travel to Asia. He had a 4 month history of recurrent

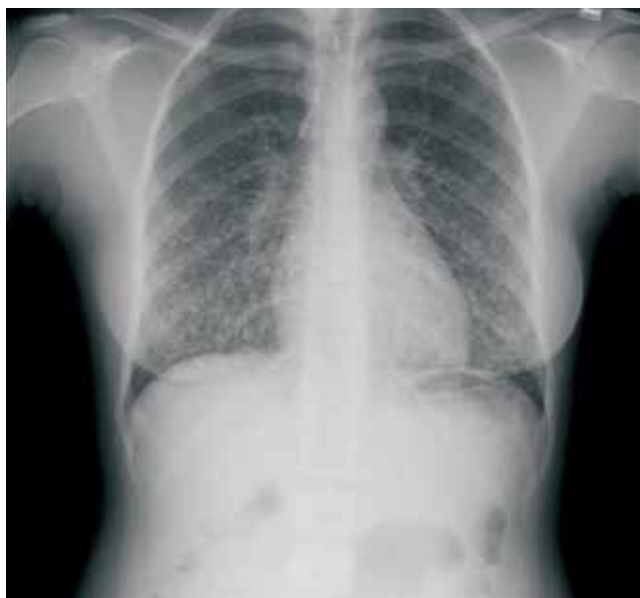

Figure 17 – CXR shows micronodular pattern. Metastatic thyroid carcinoma was the final diagnosis

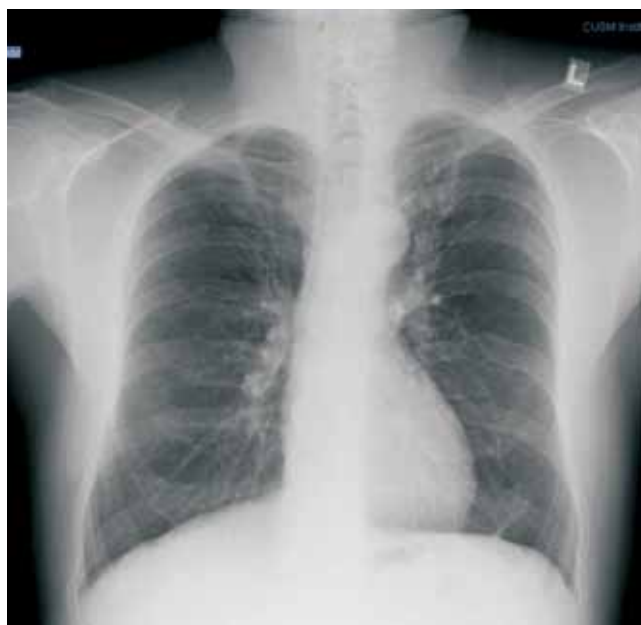


Figure 16b – CXR shows resolution

cough and fever and wheezing. He had received many courses of antibiotics, with temporary improvement. He was known to have asthma. The CXR (Figure 16a)

CLINICAL HIGHLIGHTS

- ❑ Radiology is a useful tool for diagnosis and monitoring of TB, but it should not be used alone. Microbiological diagnosis is critical to confirm TB.
- ❑ There are many radiologic manifestations of TB. TB can affect lung parenchyma, interstitium, pleura, pericardium, lymph nodes and bones.
- ❑ There are many diseases which can mimic TB, and TB can look like other diseases, so it is neither specific nor sensitive.
- ❑ HIV infection can alter the radiological appearance of TB and must be kept in mind while interpreting x-rays.
- ❑ Although one can suspect TB from the radiologic and clinical picture, confirmation of disease depends on sputum smear, PCR and culture.
- ❑ Treatment of TB purely on the basis of x-rays can result in significant over-treatment with adverse consequences for patients.
- ❑ Therefore, all persons with chest radiographic findings suggestive of TB should have sputum specimens submitted for microbiological examination.

showed a dense infiltrate in the LUL. Sputum AFB was negative but because of the history of asthma allergic bronchopulmonary aspergillosis was suspected. Serum IgE was 9,000 and aspergillus precipitins were positive. He was given a course of prednisone, with clinical and radiologic resolution (**Figure 16b**).

Figure 17 is a CXR of a 17 year old girl from Burundi. She had a 4 month history of intermittent fever and cough. Her CXR shows a micronodular pattern. Because of her country of origin and her symptoms, military TB was suspected and she was started on TB therapy. There was no improvement after 2 weeks and so a transbron-

chial biopsy was done, which revealed metastatic thyroid carcinoma. The fever was due to malaria. ■

REFERENCES:

1. Pai M. Diagnosis of pulmonary tuberculosis: what every GP should know. *GP Clinics* 2013;3:22-8.
2. Hopewell PC, Pai M, Maher D, Uplekar M, Raviglione MC. International standards for tuberculosis care. *Lancet Infect Dis* 2006;6:710-25.
3. Pinto LM, Pai M, Dheda K, Schwartzman K, Menzies D, Steingart KR. Scoring systems using chest radiographic features for the diagnosis of pulmonary tuberculosis in adults: a systematic review. *Eur Respir J* 2012.
4. Pinto L, Dheda K, Theron G, et al. Development of a Simple Reliable Radiographic Scoring System to Aid the Diagnosis of Pulmonary Tuberculosis. *PLoS One* 2013;8(1): :e54235.
5. Frieden TR. Toman's tuberculosis. Case detection, treatment and monitoring, 2nd Edition. Geneva: World Health Organization; 2004.

Let's Talk TB

Interpretation of Chest X-rays
in Tuberculosis

Questions

- 1 Which of these statements is NOT true about chest radiology for TB diagnosis?**
 - a. Chest x-rays are highly specific for TB
 - b. All persons with radiographic abnormalities suggestive of TB should have sputum specimens submitted for microbiological examination
 - c. Treatment of TB purely on the basis of x-rays can result in significant over-treatment
 - d. HIV infection can alter the radiological appearance of TB
- 2 The commonest radiologic finding in TB is:**
 - a. Pleural effusion
 - b. Upper lobe consolidation with or without cavities
 - c. Pericardial effusion
 - d. Lung nodule
- 3 TB cannot occur in the:**
 - a. Upper lobes
 - b. Lower lobes
 - c. Lingula
 - d. RML
 - e. None of the above
- 4 A patient presents with a 10 day history of high fever, cough and purulent sputum. A CXR shows a dense consolidation in the RUL. The next step is:**
 - a. Obtain sputum specimens for AFB and start TB treatment
 - b. Start a course of moxifloxacin
 - c. Obtain sputum specimens for AFB and culture/sensitivity examination and start azithromycin
 - d. Refer the patient to a TB hospital
- 5 A 55 year old 40 pack year smoker consults with you for a 2 month history of cough and blood tinged sputum (no fever). He reports that his sister had TB 10 years ago. The CXR shows a cavitory mass in the RUL. What is the next step?**
 - a. Obtain sputum AFB
 - b. Send sputum for cytology
 - c. Send patient for a bronchoscopy
 - d. Start treatment with an antibiotic

(See answers on page 48.)

Let's Talk TB

Interpretation of Chest X-rays
in Tuberculosis

CIS CME Questions begin on page 30

Answers

- 1 The correct answer is (a).** Chest x-rays are not specific for TB. Many lung infections and conditions can cause radiological abnormalities. This is why all persons with radiographic abnormalities suggestive of TB should have sputum specimens submitted for microbiological examination.¹ Only microbiological examination can confirm the diagnosis of TB.²
- 2 The correct answer is (b).** Although TB can cause any of the radiologic findings listed, upper lobe disease with or without cavitation is the most common.^{3,4}
- 3 The correct answer is (e).** Although TB most commonly occurs in the upper lobes it can occur in any part of the lung.
- 4 The answer is (c).** CXR's must be interpreted in the clinical context. An acute presentation suggests acute bacterial infection. Sputum specimens should be obtained before starting conventional antibiotics. Fluoroquinolones should be avoided if TB is at all suspected as they will result in temporary improvement because TB is sensitive to this class of drugs, leading to delay in diagnosis.
- 5 The answer is (c).** Although TB must be suspected in anyone with an upper lobe cavitory mass, in a heavy smoker with a 2 month history of cough and bloody sputum, in the absence of infectious symptoms, lung cancer must be suspected. A bronchoscopy can obtain specimens for AFB but at the same time, can make the diagnosis of cancer.

REFERENCES:

1. Hopewell PC, Pai M, Maher D, Uplekar M, Raviglione MC. International standards for tuberculosis care. *Lancet Infect Dis* 2006;6:710-25.
2. Pai M. Diagnosis of pulmonary tuberculosis: what every GP should know. *GP Clinics* 2013;3:22-8.
3. Pinto L, Dheda K, Theron G, et al. Development of a Simple Reliable Radiographic Scoring System to Aid the Diagnosis of Pulmonary Tuberculosis. *PLoS One* 2013;8(1): e54235.
4. Pinto LM, Pai M, Dheda K, Schwartzman K, Menzies D, Steingart KR. Scoring systems using chest radiographic features for the diagnosis of pulmonary tuberculosis in adults: a systematic review. *Eur Respir J* 2012.